

# Hybrid Bond and Xeno III in cervical lesions: Two year results.

C.-P. Ernst, M. Brandenbusch, G. Meyer, K. Canbek, U. Werling, and B. Willershäusen

Department for Operative Dentistry, Johannes Gutenberg-University Mainz, Germany



## Introduction:

Due to their reduction in total number of application steps and therefore for their easier use in the daily clinic, self etching adhesives are commonly used in restorative dentistry for bonding resin composite to Class V lesions.

## Aim of the study:

The aim of the study was to evaluate the clinical performance of adhesive Class V resin composite restorations utilized with two different self etching adhesives (Hybrid Bond, Sun Medical Co., Ltd.; Xeno III, DENTSPLY) according to the Ryge/CDA-criteria.

## Materials and method:

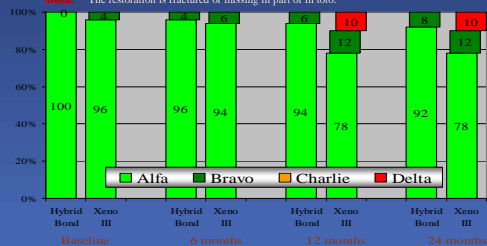
In accordance to a split mouth study design, 50 patients (57.3 SD±13.5a) received at least two comparable Class V restorations (total number: 104). The cavities were randomly assigned to the two adhesives: Hybrid Bond lot GV2 and Xeno III lot 0310000129. To obtain comparability, Filtek Supreme was used as the only restorative material in both cases. VL-curing was conducted incrementally for 40 s each (independent of the restorative material). After two years, 100 % of the restorations were available for the follow up investigation.

## Conclusion:

After two years, all Hybrid Bond restorations and showed clinically acceptable results, while 5 Xeno III restorations were lost in part or in toto. When marginal staining occurred, it mostly happened in both restorations. Stained margins very often were observed as a matter of resin composite placed on uncut enamel.

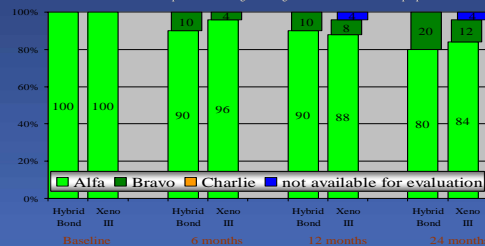
### Marginal Adaptation

**Alfa:** No visible evidence of a crevice along the margin into which an explorer will catch.  
**Bravo:** The explorer catches a crevice along the margin, but there is no exposure of dentin.  
**Charlie:** Visible evidence of a crevice with exposure of dentin.  
**Delta:** The restoration is fractured or missing in part or in toto.



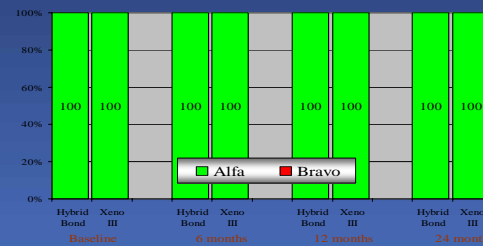
### Marginal Discoloration

**Alfa:** No existing marginal discoloration at all.  
**Bravo:** Presence of discoloration at the margins between the restoration and the tooth structure; discoloration does not penetrate along the margins of the restoration toward the pulp.  
**Charlie:** The discoloration penetrated along the margins of the restoration in a pulpal direction.



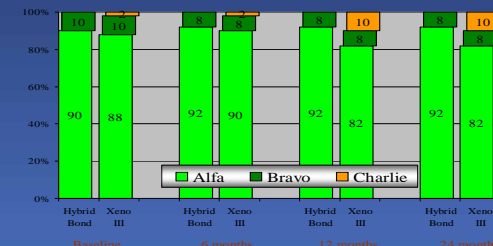
### Recurrent Caries

**Alfa:** No evidence of recurrent caries along the margin of the restoration.  
**Bravo:** Presence of softness, opacity at the margins as evidence of undermining or demineralization, or etching or white spots as evidence of demineralization in areas where explorer catches or resists removal after insertion.



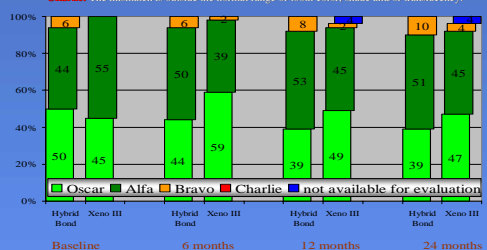
### Anatomic Form

**Alfa:** The restoration is not undercut/contoured.  
**Bravo:** The restoration is undercut/contoured, but there is no dentin exposed.  
**Charlie:** Sufficient restorative material is missing so that dentin is exposed.



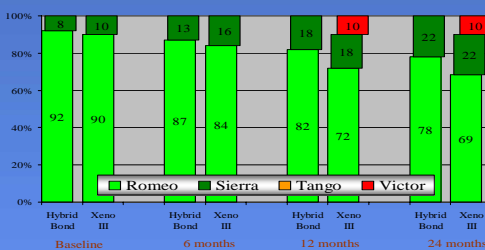
### Color Match

**Oscar:** The restoration cannot be detected with a mirror.  
**Alfa:** The restoration is visible, but there is no mismatch in color, shade and/or translucency between the restoration and the adjacent tooth structure.  
**Bravo:** There is a mismatch in color, shade or translucency, but not outside the normal range of tooth color, shade and/or translucency.  
**Charlie:** The mismatch is outside the normal range of tooth color, shade and/or translucency.



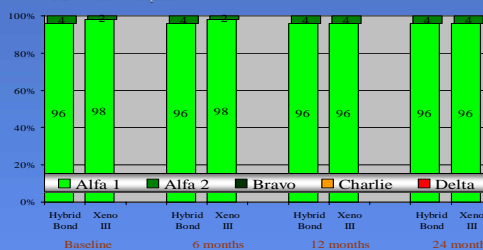
### Surface

**Romeo:** Surface is smooth, and the adjacent tissues showed no irritation.  
**Sierra:** Surface of the restoration is slightly rough or pitted but can be refinished.  
**Tango:** Surface is deeply pitted or shows irregular grooves, which were not related to the natural anatomy and could not be refinished.  
**Victor:** Surface is fractured or flaking.



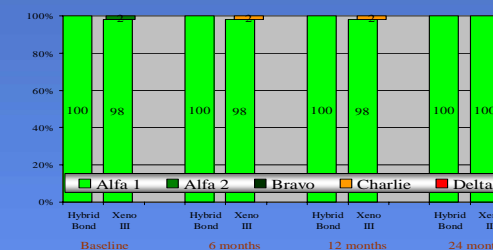
### Integrity of Tooth

**Alfa 1:** No damage of tooth structure at all.  
**Alfa 2:** Minor splinters of enamel or enamel cracks; polishable; no need for therapy.  
**Bravo:** Larger enamel cracks, where an explorer will catch, not recontourable splinters.  
**Charlie:** Enamel splinters with exposure of dentin.  
**Delta:** Fracture of cusptooth.



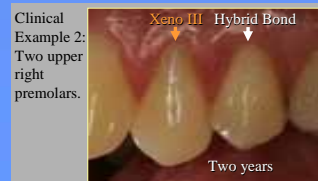
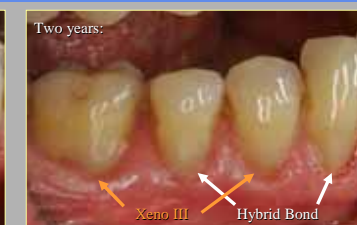
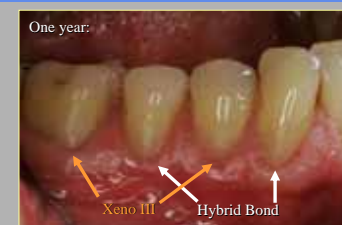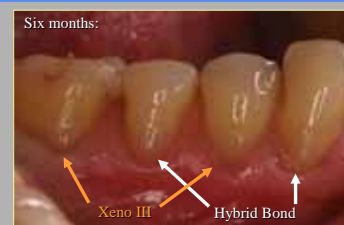
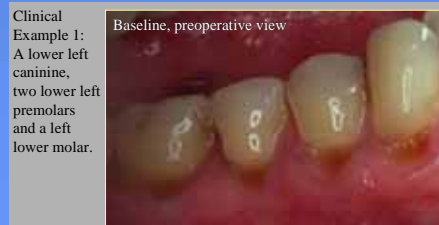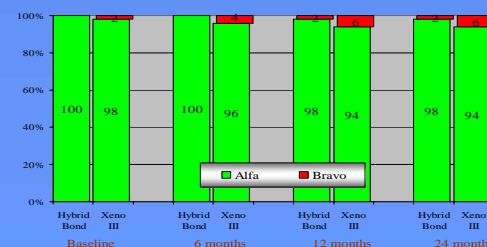
### Postoperative Sensitivities

**Alfa 1:** No complaints at all.  
**Alfa 2:** Minor complaints after placement of the restoration; no therapy necessary.  
**Bravo:** Persisting minor complaints; still no therapy necessary.  
**Charlie:** Persisting pain; treatment (removal of restoration) necessary and planned.  
**Delta:** Persisting pain; root canal treatment necessary and planned.



### Tooth Vitality

**Alfa:** Positive reaction on provocation on cold.  
**Bravo:** Negative reaction on provocation on cold.



Clinical Example 3: Two upper left premolars.

